

| No. | NAME | Age | Admitted | Died | Under the care of | Examination, at what time after death |
|-----|-----------------|-----|------------|-------|---------------------------|---------------------------------------|
| 100 | Thomas Sanders. | 20 | 26. Mch. 4 | April | J ^d Dickinson. | 49/102. |

MORBID APPEARANCES.

Gen. apper. Height 5 ft 2. Muscular. Abdomen tympanic.

Lungs: 416-1203. Firm, old, pleuritic adhesions on right side. At right apex some old tubercular masses of obsolete tubercle. The whole of the lower lobe of the right lung was quite solid, grey in colour, lacerable, sinking in water. Base of left lung much congested, no consolidation.

Heart: 1503. Muscular, left ventricle finely contracted, no valvular disease. Right side filled with clot.

Liver: 316-1103. Healthy.

Spleen 603. Not enlarged, but very soft and lacerable.

Kidney: 1503. Congested, healthy in structure.

Intestine. The only change was in the caecum, here and there the glands were enlarged, hyperaemic, showing on the surface of the gut-like small red 'split-peas'. The centre of one or two of them was ulcerated, and purulent. There was no evident enlargement of the glands of the mesentery, and no blood on the album contents.

A. M. Sheild.

No. in Reg^d 1889

NATURE OF DISEASE.

398 Pneumonia typhoid.

CASE

History.

Phthisis in family - father died of it. Patient a police constable & in excellent health - Varicella in 1881. Had been quite well up to Sunday, March 14th when had slight cold - throat sore - dysphagia painful - pains in limbs & all over body on 18th. Cough since 18th inst. when diarrhoea slight - but continuing, motions dark.

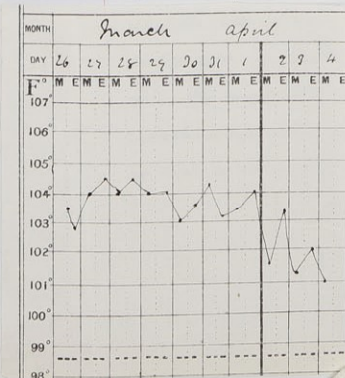
Admission.

Strongly built man - 5 coat with brown coat. P 96. Resp 26. pain referred to sternum on deep breath. Temp 102.4. Heart sounds normal. Lungs - R side pneumonia fair & clearing clear - a $\frac{1}{2}$ expiration blowing. Higher pitched pneumonia note - sharp metallic clicks in front, as far as 4th rib - expectorated pain referred to L side of sternum as far as 3rd space. Thorax. pharynx congested - uvula relaxed, slight spots of secretion on tonsils - glands under jaw swollen - tender - urine acid, sp gr 1014. no albumen. Herpes on lips.

Progress.

Though not in a very serious condition on admission, he developed next day a very high temperature. T became more than 100 - motions were loose 5 in number - no spots on abdomen. Resp 40. expectorated tubular breathing and dull at R base, with sharp expirations - moist rales on L side in front. on March 20th urine had to be drawn off with catheter - a small abscess burst over 14th dorsal vertebra - patient became worse - no purring or localised tenderness in flanks, pain delirious - motions 2 but not very loose - urine albuminous - temperature persistent about 103° - Typhoid symptoms increased - abdomen tender, but no spots appeared in the course of the disease - delirium more marked - scales on teeth & lips - He passed all motions & water under him - & from that time

semi-coma - His face was dusky, much wide open. - he dropped down to 100 - but became watery - then he was absolutely moribund in afternoon of 3rd inst - but he & relapsing again into the acute typhoid state 5 inst.



| No. | NAME | Age | Admitted | Died | Under the care of | Examination, at what time after death |
|-----|------------------|-----|-------------|-------|-------------------------|---------------------------------------|
| 100 | Thomas Saunders. | 20. | 16. Nov. 4. | April | J ^r Dickson. | 4 1/2. |

MORBID APPEARANCES.

Gen. apper. Height 5 ft 2. Muscular. Abdomen tympanic.

Lungs. 4 1/6 - 12 oz. Firm, old, pleuritic adhesions on right side. At night open some old tubercles. The whole of the lower lobe of the right lung was quite solid, grey in colour, lacinated, sinking in water. Base of left lung much congested, no solidification.

Heart. 15 oz. Muscular, left ventricle firmly contracted, no valvular disease. Right side filled with clot.

Liver. 3 1/6 - 11 oz. Healthy.

Spleen 6 oz. Not enlarged, but very soft and lacinated.

Kidney. 15 oz. Congested, healthy in structure.

Intestine. The only change was in the caecum, here and there the glands were enlarged, hyperemic, showing in the surface of the gut like small red spots. The centre of one or two of them was ulcerated, and purulent. There was evident enlargement of the glands of the mesentery, and no blood on the alvini coat.

W. M. Shield.

| No. in Reg ^y 1884 | NATURE OF DISEASE. |
|------------------------------|--------------------|
| 398 | Pneumonia typhoid. |

CASE.

History: Father's in family - father died of it. Patient a police constable & in excellent health - Variola in 1881. Had been quite well up to Sunday, March 14th when had slight cold - throat sore - deglutition painful - pains in limbs & all over body on 18th. Cough since 16th inst., when diarrhoea slight - but continuing, stool dark.

Admission: Strongly built man - T coated with brown coats. P 96. Resp 36. Pain referred to sternum on deep breath - Temp 102.4. Heart's sounds normal. Lungs - R side pneumonia fair obscuring clear - a L coughing blowing, higher pitched pneumonia note - sharp metallic clicks in part, as far as 4th rib - expectorated pain referred to L side of sternum as far as 3rd space. Throat. Pharynx coated with white exudate, slight spots of ecchymosis on tonsils - glands under jaw swollen - tender - urine acid, sp gr 1.014. No albumen. Herpes on lips.

Progress: Though not in a very serious condition on admission, he developed week by week a very high temperature. T became one hour - & mittens were lost - 5 in between 10 spots on abdomen. Resp 40. Expectorated tubercle containing and vile at R base, with sharp crepitations - moist rales on L side in part - on March 20th urine had 1000 diam off with catheter - a small abscess burst over 1st lumbar vertebra - & patient became worse - no purring or localized tenderness in flanks. Semi delirious - mittens 2 but not very loose - urine albuminous - temperature persistent above 103° - Typhoid symptoms increased. Abdomen tender. No spots appeared in the course of the disease - delirium more marked - sores on teeth & lips - He passed all motions & water under him - & from that time relapsed into a state of semi-coma - His face was dusky, mouth wide open. Sores accumulable. He dropped down at 10.00 - but became watery - tremor of hands marked - he was absolutely moribund on afternoon of 3rd inst - but rallied through some space - & relapsing again into the acute typhoid state he died on morning of 4th inst.