

No.	NAME	Age	Admitted	Died	Under the care of	Examination, at what time after death
312	Emily Stahl.		10 th Sept.	15 th Sept.	Dr Owen	

MORBID APPEARANCES.

Throat.

Well nourished body. RMR present. Abscess on L side of face.
Faint linea gravidarum on abdomen. Atrophy of recti muscles
Pleurae. Nil.

Lungs R. 17 oz. Both are redematous. Otherwise they are healthy.
L. 16 oz.

Pericardium nil.

Heart = 10 oz. With the exception of very faint striation of the muscle, the
heart is healthy. The coronary vessels are normal.

Abdomen

Abdomen. No peritonitis.

Liver = 3 lbs 10 oz. normal.

Spleen = 7 oz. normal.

Pancreas rather soft.

Kidneys 6 oz each. Both large but apparently healthy.

Bladder normal.

Uterus The os is that of a parous uterus & has a small
old laceration. The uterus is a little large. The mucous
membrane is thick & shagreened & appears in the condition of menstruation.
Part of old corpus luteum in R ovary. A few small cysts in the
left ovary.

Alimentary Canal. The stomach is distended with food which
must have been ingested shortly before death. The stomach
& intestines appear healthy.

Cranium

Cranial contents. The meninges are healthy. There is
no hemorrhage or fracture of skull.

Brain = 3 lbs 4 oz. Healthy.

No. in Reg^t
1907.

NATURE OF DISEASE.

1883

Distended stomach. Faint striation of heart muscle.

CASE.

Brought in dead.

From page 314.

— Glands enlarged. Sept 4. Tubercular Br more white upper lobe
of R. lung - diminished over entire lower lobe, but no calcareous.
Pleural blood stained - Oedema of pericardium, less. Sept 12, Venous
3rd - relieved - Sept 14. Induration of lower thorax & upper
abdominal region - Ears were very cyanosed - Wasting disease
16 Sept. Oedema of face & neck much increased - Delirious -
17 " - Died 6 a.m. -

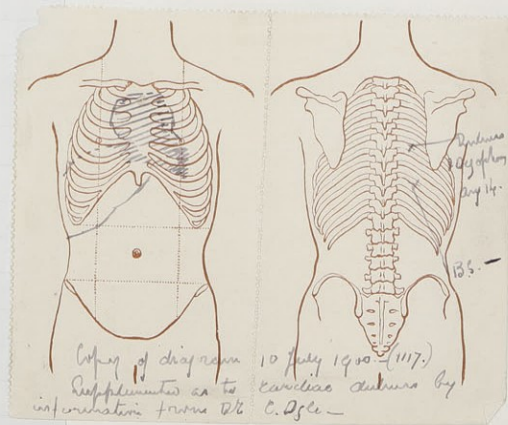
Treatment

Ureophis - Venesection - Pyrexia - Styracis resin - Bark &c.

W. S. L. S. S.

Sept 23. 07

This case has been entered as Frederick - Henry - & Edward Taylor -



1900 under Dr. G. G., under the name
the 4th of that month he had been
the chest, & increased by cough or deep
his chest more or less severe for 5
in pencil - No of notes 1117 - July 1900.
heart disease during the previous
unstable - He had Enteric in 1898 - Had
Syphilis -
2nd at apex, & at apex in 5 sp. n. p.
fracture - Syphilis & disintegrated soft
entire of lung capsule - Pulmonary
edge 3 fingers breadth below costal margin
July 13. Pleural fistula; V.R. & Br. L.S. -

from spine of 2nd coccygia to base - Dysphagia at both bases. Died
Aug 14.

No.	NAME	Age	Admitted	Died	Under the care of	Examination, at what time after death
312	Emily Skill.		15 th Sept.	15 th Sept.	Dr Owen	

MORBID APPEARANCES.

Throat.

Well nourished body. RNR present. Abrasion on L side of face.
Faint linea gravidarum on Abdomen. Distension of Recti muscles

Pancreas. nil.

Lungs P. 17 oz. L. 16 oz. Both are oedematous. Otherwise they are healthy.

Pericardium nil.

Heart = 10 oz. With the exception of very faint distension of the muscle, the heart is healthy. The coronary vessels are normal.

Abdomen

Abdomen. No peritonitis.

Liver = 3 lbs 10 oz. normal.

Spleen = 7 oz. normal.

Pancreas rather soft.

Kidneys 6 oz each. Both tough but apparently healthy.

Bladder normal.

Uterus The os is that of a parous uterus & has a small old laceration. The uterus is a little large. The mucous membrane is thick & shagreened & aptly - the condition of menstruation.

Scar of old corpus luteum in R Ovary.
Left ovary.

Alimentary Canal. The stomach is must have been in good shape & intestines appear healthy.

Genitalia

Genital anatomy. The os is that of a parous uterus & has a small old laceration. The uterus is a little large. The mucous membrane is thick & shagreened & aptly - the condition of menstruation.

Breast = 3 lbs 4 oz. Healthy.

No. in Reg.
1907.

NATURE OF DISEASE.

1583

Distended stomach. Faint distension of heart muscle.

CASE.

Brought in dead -

From page 314.

Glands enlarged. Sept 4. Tubercles Br. over whole upper lobe of R. lung - disinclined air entering lower lobe, but no clubbing. Sputum blood stained - Oedema of Pericardium, less. Sept 12, Venous 3rd - relieved - Sept 14. Induration of lower thorax & upper abdominal region - Ears were very cyanosed - Murmuring delirium. 16 Sept. Oedema of face & neck much increased - Delirious - 17 " - Died 6. a.m. -

Treatment

Ureoplin - Venesection - Oxygen -strychnine - Park St.

Wet cloths.

Sept 23. 1901

This case was been entered as Frederick - Heavy - & Edward Taylor. He was in the Feder in July 1900 under St. J. G., under the name of Heavy Taylor. He stated that on the 4th of that month he had been seized with pain all over - worse in the chest, & increased by cough or deep breath - that he had had pains in his chest more or less severe for 3 or 4 years - (Months are then written in pencil - No of notes 1117 - July 1900) he had been treated at home for heart disease during the previous winter - His family history was rheumatic - He had Enteric in 1898 - Had also had dysentery - No mention of Syphilis -

Exameⁿ. Marked pulsation in a^{2d} & 3^d spaces, & at apex in 5 sp. 21. P. Cl. third at apex, with loud rough friction - Systolic & diastolic soft murmur just above the apex - Air entry of lung capillary - Nodules above angle of scapula - Liver tender, edge 3 fingers breadth below costal margin - Costal & pedunc^l rounded, red +. Cuv 13. Pleural friction; V.R. & Br. 20 - , from spine of 2^d scapula to base - Dysphagia at both bases. Ridsⁿ Aug 14.