

No.	NAME	Age	Admitted	Died	Under the care of	Examination, at what time after death
318	Alice Barnett	22	Oct 14 th	Oct 29 th	D. Whelan	29 hours

No. in Reg ^d 1884	NATURE OF DISEASE.
1131-	Pyæmia -

MORBID APPEARANCES.

General condition Height 5 feet 5 inches Hair light.
Body well nourished.

Cervical Lungs. There are no adhesions. 3 pounds 12 ounces. Both lungs are congested and oedematous. The apex of the left is consolidated (parts cut firm in water).

Pericardium Heart. Healthy. 8 ounces. Cardiac muscle healthy - Valves healthy.

Centrum Liver. Healthy. 2 pounds 4 ounces. Capsule smooth: substance congested.

Spleen. 6 ounces. Capsule smooth: substance congested.

Pancreas. Healthy.

Kidneys. 14 ounces. Capsule not adherent: substance bright in colour sugar free.

Bladder. Healthy.

Stomach Intestines. Healthy. Slightly congested.

Uterus. The uterus is enlarged. Its length is $3\frac{1}{2}$ inches: breadth $2\frac{1}{2}$. The walls in some places are $\frac{1}{2}$ inch in thickness. The length of the cervix is $1\frac{1}{2}$ inches: it is hollowed by a thinning of the mucous membrane of the uterus is thickened, especially near the fundus on the left side where the vessels are considerably enlarged. No fetal membranes are to be found.

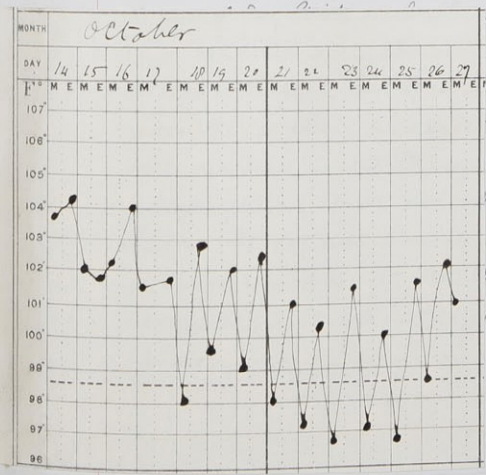
Continued on p 276.

CASE.

History. The patient, a housemaid, had been ailing three months, & on Oct 8th fainted, & taking to her bed was delirious for 2 days. On Oct 12th she had acute pain in the R leg, which in the left, subsequently the shoulder painful. She had no history of wounds, or discharges - a recent parturition was discarded on account of menstruation beginning the day of admission.

Admission. A well nourished pale woman - who had a very high temperature, pulse of 140 - but nothing abnormal in heart, lungs, or abdomen. She complained of pain in the R shoulder, & presented slight effusion into the L kneejoint - with swelling & pain in the L thigh & leg, & thickening along the course of the saphena vein (internal). She was menstruating slightly - & presented more the appearance of rheumatism & phlebitis than anything else.

Progress. A red black speckle came on the R thigh, with swelling of the R leg, which went down - but the left leg was always swollen & painful, as was also the L thigh. She slept badly, had a high & irregular temperature, with flushed face, coated tongue, & quick pulse - the latter averaging 112 - She had however no rigors - or sweats - but on the 9th day she developed



the pharynx - soft palate & tonsils - her glands under the jaw were with a swelling as well as with fluctuation articulation - This subsided somewhat - cleared up to a slight extent - but the rain pained, & she died on the 14th day, & towards the evening being temp. 98, & soon - the throat being wiped (-3i) - Pot Wine 3iii being substituted

H. T. Griffiths.

No.	NAME	Age	Admitted	Died	Under the care of	Examination, at what time after death
318	Alice Barrett	22	June 14 th	June 27	Dr. Wysham	29 hours.

No. in Reg^t
1884

NATURE OF DISEASE.

1131- Pyæmia -

MORBID APPEARANCES.

General condition Height 5 feet 5 inches Hair light.
Body well nourished.

Cervicæ. There are no adenoids.

Lungs. 3 pounds 12 ounces. Both lungs are congested and oedematous. The apex of the left is emphysematous (part cut from it sunk in water) -

Pericardium Healthy.

Heart. 8 ounces. Cardiac muscle healthy - Valves healthy.

Peritoneum Healthy.

Liver 2 pounds 4 ounces. Capsule smooth: substance congested.

Spleen 6 ounces. Capsule smooth: substance congested.

Pancreas Healthy.

Kidneys 1 1/2 ounces: Capsules not adherent: subcapsular even.

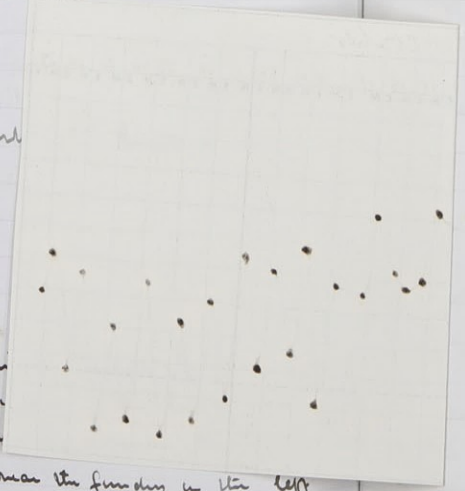Bladder Healthy.

Stomach Healthy.

Intestines Slightly congested.

Uterus The uterus is enlarged: its length is 3 1/4 inches. The walls in some places are 1/2 inch in thickness: it is relaxed by a tense membrane of the uterus is thickened, especially near the fundus in the left side where the vessels are considerably enlarged. No fetal membranes are to be found.

Continued on p 276.



CASE.

History. The patient, a housemaid, had been ailing three months, & on Oct 8th fainted, & taking to her bed was delirious for 2 days. on Oct 12th she had acute pain in the R leg, which in the left, subsequently the shoulder painful. She had no history of wounds, or discharges - a recent parturition was discarded on account of menstruation beginning the day of admission.

Admission. A well nourished pale woman - who had a very high temperature. pulse of 140 - but nothing abnormal in heart, lungs, or abdomen. She complained of pain in the R shoulder, & presented slight effusion into the L kneejoint - with swelling & pain in the L thigh & leg, & thickening along the course of the Saphena vein (internal). She was menstruating slightly - presented more the appearance of rheumatism & phlebitis than anything else.

Progress. A red black speckle came on the R thigh, with swelling of the R leg, which went down - but the left leg was always swollen & painful, as was also the L thigh. She slept badly, had a high & irregular temperature, with flushed face, coated tongue, & quick pulse - the latter averaging 112 - She had hæmaturia in urine - or in sputa - but on the 9th day she developed a mass of grey fibrin membrane on the pharynx - soft palate & tonsils - her urine exhibited some albumen. The glands under the jaw were not enlarged or tender - but that day a swelling was well out - with fluctuation - under the R sterno-clavicular articulation - This subsided somewhat - the membrane on the throat cleared up to a slight extent - but the patient's general health did not improve, & she died on the 14th day. She was treated with Quinine, & Iron, afterwards the Quinine being in an acid mixture, with Acid Phosph. oil, & Iron - the throat being wiped at intervals with acid lactic (800-3i) - Pot-Dine 3iii being substituted for Iron.

H. T. Griffiths.