No.	NAME	Age	Admitted	Died	Under the care of	Examination, at what time after death
88	George Pattison	4½	March 6th	Mar 13th	Dr. Wadham	53 hrs.

MORBID APPEARANCES

Gen. Condition. Well nourished. Face blotchy. hair brown.
Hardly any œdema of legs.

Lungs. Compressed & somewhat carnified.

Heart. 4 oz: not contracted
natural in all respects.

Liver. fatty change 1½ lb: fatty: gall bladder empty.

Spleen. 3 oz: natural.

no lund accoms reaction.

Kidneys Large white. 7 oz: large: mottled white.
Surface smooth: capsule
slightly adherent in places.

Peritoneum. Distended with puriform fluid.
Chronic peritonitis. Surface of intestines roughened only here and there.
Signs of congestion on parietal pericardium: a little here & there on the visceral.
No perforation of intestine.

Barnard Wahn.

No. in Regr 1880	NATURE OF DISEASE
303	"Large white Kidneys." Peritonitis.

CASE

History. The patient had measles & chicken pox at 2½ yrs, from this time there had been a discharge from the ears noticed, otherwise his health had been good.
A fortnight before admission his mother had noticed a rash all over his body, accompanied with a little soreness of throat, feverishness & the discharge from the ears. Only 3 days before admission was the dropsy noticed, he complained of headache & pain in the back. There was slight diarrhœa. The urine was not noticed. Vomiting occurred occasionally, at first with the appearance of the rash.

On Admission There was general œdema face, abdomen, penis, scrotum & legs. — Skin peeling.

Mar. 6. Sore-throat: headache: pain in loins. Redness of throat. White coated tongue.

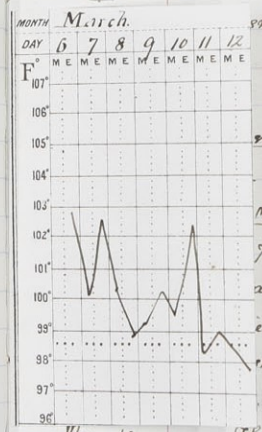

small & rapid. Resp. quiet.
at bases a few large bronchitic sounds.
a soft systolic bruit heard all over the cardiac area.
abdomen distended: faint fluctuation at lower part.
smoky: loaded with albumen.
Mar. 7 Mag: Sulph 3ß ℞: Digitalis ♏ x. Aq 3ß. 4th hors.
7th an erysipelatous blush appeared on the face, cheeks & upper lip. A line with AgNO3 drawn from the inner angle of the L. eye to the L. angle of mouth, the blush was limited by it on the mucous of the 8th but the swelling & redness of the opposite side was said to have had as much as that on the L. By the 10th the red blush had quite disap. the œdema persisted, less as elsewhere.

Mar. 10. The medicine was omitted on the 10th, he had several attacks of vomiting that morn. The Bowels were very freely open, on the 12th Hyd: Chlorid gr j. Pulv Salap: Co ʒß VIII were given, the bowels acting 7 times during the following night.
From the 10th the patient "gradually sank", vomiting continued. There were no convulsions.

Mar. 13. He died on the 13th at 10 A.M.

J. J. Macwhirter Dunbar.

No.	NAME	Age	Admitted	Died	Under the care of	Examination, at what time after death
88	George Pattison	4½	March 6th	March 13th	Dr. Wadham	53 hrs.

MORBID APPEARANCES

Gen. Condition. Well nourished. Face blotchy. hair brown.
Hardly any œdema of legs.

Lungs. Compressed & somewhat carnified.

Heart. 4 ℥: not contracted
Natural in all respects.

Liver. fatty change 1½ lb: fatty: gall bladder empty.

Spleen. 3 ℥: natural.

no lead accession.

Kidneys Large white. 7 ℥: large: mottled white.
Surface smooth: capsule
slightly adherent in places.

Peritoneum. Chronic peritonitis. Distended with puriform fluid.
Surface of intestines roughened only here and there.
Signs of congestion on parietal pericardium: a little
there on the visceral.
No perforation of intestine.

Barnard Wahr.

No. in Regr 1880	NATURE OF DISEASE
303	"Large white Kidneys." Peritonitis.

CASE

History. The patient had measles & chicken pox at 2½ yrs, from this time there had been a discharge from the ears noticed, otherwise his health had been good.
A fortnight before admission his mother had noticed a rash all over his body, accompanied with a little soreness of throat, feverishness & the discharge from the ears. Only 3 days before admission was the dropsy noticed, he complained of headache & pain in the back. There was slight diarrhœa. The urine was not noticed. Vomiting occurred occasionally, at first with the appearance of the rash.

On Admission Mar. 6. There was general œdema face, abdomen, penis, scrotum & legs. — Stern peeling.
Sore-throat: headache: pain in loins. Redness of throat: White coated tongue.
P. small & rapid. Resp. quiet.
Lungs at bases a few large bronchitic sounds.
Heart a soft systolic bruit heard all over the cardiac area.
Abdomen distended: faint fluctuation at lower part.
Urine smoky: loaded with albumen.

Mar. 7 Mag. Sulph ʒß ℞ Digitalis ♏ x. Aq ℥ß. 4th hors.

On the 7th an erysipelatous blush appeared on the face, cheeks & upper lip. A line with AgNO3 was drawn from the inner angle of the L. eye to the L. angle of mouth, the blush was limited by this line on the morn. of the 8th but the swelling on the opposite side was said to have diminished as much as that on the L. By the 10th the red blush had quite disappeared, the œdema persisted, here as elsewhere.

Mar. 10. The medicine was omitted on the 10th, he had several attacks of vomiting that morn. The Bowels were very freely open, on the 12th Hyd. Chlorid. gr j. Pulv. Jalap. Co. gr viij were given, the bowels acting 7 times during the following night.
From the 10th the patient "gradually sank", vomiting continued. There was no convulsions.

Mar. 13. He died on the 13th at 10 AM.

J. J. Macwhirter Dunbar.