

No.	NAME	Age	Admitted	Died	Under the care of	Examination, at what time after death
387	Thomas Argent	30	Dec 8	Dec 13	D ^r Dickinson	15 hours

MORBID APPEARANCES

Gen. Appearance - Height 5ft 8in. Hair Brown - Body thin -

Spots - a few small reddish brown spots on Chest, sides of abdomen & thighs -

Plaques - a few old arular adhesions on left side -

Adhesions - The posterior borders of each lung on section of a very red color, frothy serum escaping on pressure, crepitation floats in water.

Congestion - Anterior portions healthy -

Heart - 14 oz Uncontracted -

Muscle Soft - Partly decolorised clots in each ventricle

Pale & abnormal - Muscle softer, paler, & more friable than usual -

friable - All valves & orifices normal -

Liver - 4 lbs 13 oz. Surface smooth

Healthy - On section is pale than normal, otherwise healthy -

Spleen - 15 oz Enlarged, & full of blood - otherwise healthy -

Enlarged -

Kidneys - 16 oz. Capsule not adherent

Congestion - Cortex & pyramids in fair proportion very full of blood -

Intestines - On the last four feet of ileum, Peyer's patches, enlarged & congested, some of these glands as well as some of the solitary glands were ulcerated, the ulcers being oval in shape, with thickened & irregular edges, surface clean

Ulcers in ileum -

No. in Reg^t 188 2 NATURE OF DISEASE.

1580 Typhoid Fever, Congestion of Lungs.

CASE

History - It was not found possible to obtain any very accurate history in detail either from the patient or his friends. He had been engaged as a carman for several years and of temperate habits but for 14 weeks before admission had been out of work & had been prevented by poverty, from getting adequate food. About a month before admission he laid in bed several days with 'a cold'. No ... but great debility. Recovery ...

387 Continued - Tho Argent
 Ulcers numerous near ilio caecal valve. The crumens membrane in the neighbourhood of the ulcers & enlarged glands crumens impeded with blood vessels. The crumens glands enlarged.

No ulceration in colon.

D: M: Ross.

... increasing ... suddenly worse ... noticed on body ... for 3 nights ... of great prostration ... arms & legs are also over abnorm ... choical papules ... abundant food ... leaking ... no distention ... urine acid, yesterday, not urine.

TEMP	100°	99°	98°	97°	96°
PULSE	112	110	108	108	110
RESPIR	24	24	24	24	24
DAY OF DISEASE	0	5	6	5	

... treated with Quin sulph gr iii ter die, a dose of stramonium increased in Nalox 3x to Brandy 3xii with Brandy 3xix to 3xv. not gain in any respect after admission, but sank into a more constant muttering delirium, with an expression of dejection - a few of the papules which faded at first under ... become petechial, a few fresh subcutaneous haemorrhages appeared. ... then was moderate diarrhoea; motions loose & rather dark, no blood passed: no apparent abdominal pain or tenderness. At 9 am on 13th he had a sudden & very severe sweat, drenching the clothes & sheets & after it lay in a condition of extreme collapse, with deep venous congestion of the skin, complete unconsciousness. The pulse, respirⁿ & temp. rose rapidly and if his temp. had reached 107° & his strength seemed adequate a cold bath was advised, but his temp. did not exceed 106° & he died at 11.30 P.M. A.T. Myers.

No.	NAME	Age	Admitted	Died	Under the care of	Examination, at what time after death
387	Thomas Argent	30	Dec 8	Dec 13	Dr. Dickinson	15 hours

MORBID APPEARANCES

Gen. Appear. Height 5ft 8in. Hair Brown - Body thin -
Spots - a few small reddish brown spots on Chest, sides of abdomen & thighs -
Plaques a few old annular adhesions on left side -
Admissions
Congestion

Heart -
Muscle soft
Pale & abnormal
friable

Liver -
Healthy -

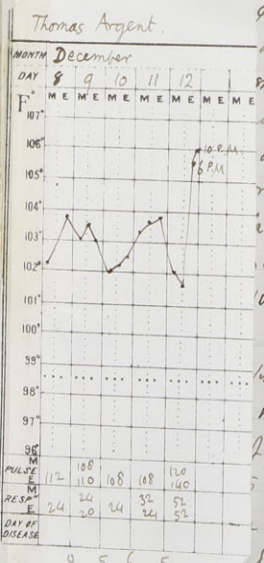
Spleen 15 oz Enlarged, & full of blood - otherwise healthy -
Enlarged
Kidneys 16 oz. Capsule not adherent
Congestion Cortex & papillae in fair proportion very full of blood -
Intestines In the last four feet of ileum, Peyer's patches enlarged & congested, some of these glands as well as some of the solitary glands were ulcerated, the ulcers being oval in shape, with thickened & irregular edges, surface clean

No. in Reg ^r 188 2	NATURE OF DISEASE.
-------------------------------	--------------------

1580 Typhoid Fever, Congestion of Lungs.

CASE

History. It was not found possible to obtain any very accurate history in detail either from the patient or his friends. He had been engaged as a carman for several years and of temperate habits but for 14 weeks before admission had been out of work & had been prevented by poverty from getting adequate food. About a month before admission he laid in bed several days with a cold, no diarrhoea, cough or acute symptoms, but great debility. Recovery incomplete - headache & loss of appetite persisting - & increasing during a fortnight before admission. On Dec. 3 he became suddenly worse, & diarrhoea set in; some small dark purple spots noticed on body & legs: motions reported light, no melaena - Delirium for 3 nights. On admission, 4th Dec. P.M. A very cachectic man in a state of great prostration -



guae compressed: no active delirium - much tremor & shuddering; al fluctatio. Over the whole trunk esp. of arms & legs are small round subcutaneous haemorrhages; and also over abdomen an unusually abundant crop of large typhoidal papules; on 10th, thick brown fur in the centre, edges raw: abundant food & like teeth almost preventing him from speaking. Ur: 104. Heart: sounds sharp. Abdomen: no distention; no tenderness; no Kocher's sign etc. Urine: acid, 1011 slightly albuminous. Bowels open yesterday, not since. treated with Quin sulph gr iii ter die, & doses of stramonium increasing in Ratio 3x to Brandy 3xii with Brandy mixture 3iv. not gain in any respect after admission, but sank into a more constant muttering delirium, with an expression of dejection - a few of the papules which faded at first - under became petechial, a few fresh subcutaneous haemorrhages appeared. On 12th there was moderate diarrhoea; motions loose & rather dark, no blood passed: no apparent abdominal pain or tenderness. At 9 a.m. on 13th he had a sudden & very severe sweat, drenching the clothes & sheets & after it lay in a condition of extreme collapse, with deep venous congestion of the skin, complete unconsciousness. The pulse, respir. & temp. rose rapidly and if his temp. had reached 107° & his strength seemed adequate a cold bath was advised, but his temp. did not exceed 106° & he died at 11.30 P.M. A.T. Myers.

No.	NAME	Age	Admitted	Died	Under the care of	Examination, at what time after death
387	Thomas Argent	30	Dec 8	Dec 13	Dr. Dickinson	15 hours

MORBID APPEARANCES

Gen. Appearance Height 5ft 8in. Hair Brown - Body thin -

Spots - A few small reddish brown spots on Chest, sides of abdomen & thighs -

Plaques - a few old annular adhesions on left side -

Adhesions -

Congestion -

Heart - Muscle soft - Pale & abnormal friable

Liver - Healthy -

Spleen - Enlarged. 15 oz. Eubacter. & full of blood - otherwise healthy -

Kidneys - 16 oz. Capsule not adherent

Congestion - Cortex & pyramids in fair proportion very full of blood -

Intestines - On the last four feet of ileum, Peyer's patches enlarged & congested, some of the glands as well as some of the solitary glands were ulcerated, the ulcers being oval in shape, with thickened & irregular edges, surface clean

Ulcers in Ileum -

No. in Reg ^t 188 2	NATURE OF DISEASE.
1580	Typhoid Fever, Congestion of Lungs.

CASE

History. It was not found possible to obtain any very accurate history in detail either from the patient or his friends. He had been engaged as a carman for several years and of temperate habits but for 14 weeks before admission had been out of work & had been prevented by poverty from getting adequate food. About a month before admission he laid in bed several days with 'a cold', no diarrhoea, cough or other symptoms, but great debility. Recovery incomplete - headache & loss of appetite persisting - & increasing about a fortnight before admission. On Dec. 3 he became suddenly worse, & diarrhoea set in; some small dark purple spots noticed on body & legs: motion reported light, no melaena - Delirium for 3 nights.

On admission - Dec. 6. A very cachectic man in a state of great prostration - intelligence confused: no active delirium - much tremor & shivering; occasional fluctuation. Over the whole then esp. of arms & legs are many small round subcutaneous haemorrhages; and also over abdomen and back an unusually abundant crop of large typhoidal papules; Tongue dry, thick brown fur in the centre, edges raw: abundant foulordes on lips & teeth almost preventing him from speaking. Pulse fair: 104. Heart sounds sharp. Abdomen. no distention & retraction: no tenderness: no Richter's sign etc. Urine. acid, sp. gr. 1011 slightly albuminous. Bowels open yesterday, not since.

Prognosis. He was treated with Quin sulph gr iii ter die, & doses of stramonium increased from Un. Nalvi ʒss to Brandy ʒvi with Brandy mixture ʒvi. He did not gain in any respect after admission, but sank into a state of more constant muttering delirium, with an expression of anxious depression - a few of the papules which faded at first under pressure became petechial, a few fresh subcutaneous haemorrhages appeared. After Dec. 8 there was moderate diarrhoea; motions brown & rather dark, no blood passed: no apparent abdominal pain or tenderness. At 9 am on 13th he had a sudden & very severe sweat, drenching the clothes & sheets & after it lay in a condition of extreme collapse, with deep venous congestion of the skin, complete unconsciousness. The pulse, respir. & temp. rose rapidly and if his temp. had remained 107 & his strength seemed adequate a cold bath was advised, but his temp. did not exceed 106 & he died at 11.30 P.M.

A.T. Myers.