

No.	NAME	Age	Admitted	Died	Under the care of	Examination, at time after death
128	Harrist Allport	48. 27 th Ap.	May 5	D. Dickinson	28 hours	

MORBID APPEARANCES

Gen Appearance Very fat 5 ft 2 in.

Lungs. These organs were much congested, so as to be of a much deeper colour, & to contain much more fluid blood than natural.

Congestion Careful dissection failed to find any obstruction in the larger or smaller branches of the Pulmonary artery of either side.

Pericardium. Distended with turbid, slightly blood stained fluid.

Distension & Inflammation Its inner surface of a deep colour, & rough from the presence of injected vessels.

Heart. Its pericardial investment is generally inflamed, and near the right border of the organ & about 1 1/2 inches above the apex is a small abscess of about the size of one's little finger nail.

Abscess of substance. This abscess caused a marked projection on the surface & contained a small quantity of healthy pus. It had not opened externally.

Endocarditis The anterior wall of the right ventricle when examined internally, in the situation of the abscess, presented a hot rough patch of yellowish discoloration. This inflamed patch was evidently due to the presence of the abscess, but it did not appear on careful examination that the abscess had actually penetrated into the ventricle.

The heart weighed 10g and presented nothing further for remark.

Courtesy on 121.

No. in Reg ^d 1882.	NATURE OF DISEASE.
549.	Pericarditis Abscess of Heart Endocarditis Congestion of the Lungs.

CASE

History. The patient could give no history of previous illness. Menstruation habitually regular & normal. She describes no morbid symptoms of any kind until, 3 days before admission, she had a severe riga with much vomiting. She was then living as cook in a London family. She describes the house as smelling offensively of the drainage, a housemaid living in the same house had been laid up with diarrhoea about a week before the patient began to feel ill, and was recovering.

Several severe paroxysms came on at night during the week before admission. Much headache and dry throat: no diarrhoea, no abdominal pain.

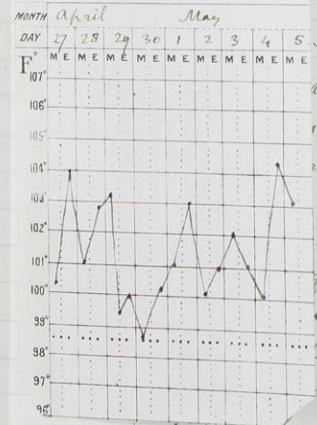
on admission. Ap. 17. Aneur. 6. A well nourished woman - not flushed; skin fairly cool and dry (3 p.m.). Expression cheerful and intelligence good.

Subacute headache: much weakness. P. 110 fairly good. Ref. 20. Tongue thickly coated. Heart sounds rather distant, otherwise normal. Lungs a few bronchitic sounds. Abdomen normal - Urine acid. Sp. 105. Slightly lithaemic, a trace of album.

Paroxysms. She was treated on admission with Hops, Sassafras, gr. i. hu. Hot Rhei. ʒ. i. q. n. Three loose light motions were passed next morning. She had a violent

Harrist Allport. Anon. 6. 17th - 29th, again on aft. 19th. a severe riga on night in all occasions with much sweating & flushing - but entirely a headache. No abnormality in the heart sounds - slight was continued. No riga after 30th. but nearly continuous, rises with much flushing. She was treated with Quin Sulfhy. ʒ. i. from the 29th April onwards - and was in no further what seemed to arise from the sweating and hyperæcæmia.

17th May 4 she first made complaint of pain in her left side grew acute. She compared it to the running of a gear into her divisions during the greater part of the night May 4-5. when she about 9.30 am on morning of 5th she complained of no further & sounds were faintly audible but not otherwise abnormal; she died quietly, two hours later.



A.T. Myers.

No.	NAME	Age	Admitted	Died	Under the care of	Examination, at the time after death
128	Harriet Allcock	48	27th Apr.	May 5	D. Dickinson	28 hours

MORBID APPEARANCES

Gen. Appearance Very fat. 5 ft 2 in.

Lungs. These organs were much congested, so as to be of a much deeper colour, & to contain much more fluid blood than natural.

Congestion Careful dissection failed to find any obstruction in the larger or smaller branches of the Pulmonary artery of either side.

Pericardium. Distended with turbid, slightly blood stained fluid.

Distension & Inflammation of the inner surface of a deep colour, & rough from the pressure of injected vessels.

Heart. The pericardial investment is generally inflamed, and near the right border of the organ & about 1 1/2 inches above the apex is a small abscess of about the size of one's little finger-nail.

Abscess of substance. This abscess caused a marked projection out face & contained a small quantity of fecid pus. It had not opened externally.

Endocarditis The anterior wall of the right ventricle where internally, in the situation of the abscess, is a hot rough patch of yellowish discolouration. This inflamed patch was evidently due to the pus of the abscess, but it did not appear on careful dissection that the abscess had actually penetrated the ventricle.

The heart weighed 10 1/2 oz. Presented nothing further for remark.

Continued on 121.

No. in Reg ^d 1882.	NATURE OF DISEASE.
-------------------------------	--------------------

549 Pericarditis Abscess of heart Endocarditis
Congestion of the Lungs.
CASE

History. The patient could give no history of previous illness. Menstruation habitually regular & normal. She describes no morbid symptoms of any kind until, 8 days before admission, she had a severe rigors with much vomiting. She was then living as cook in a London family; she describes the house as smelling offensively of the drainage, a housemaid living in the same house had been laid up with diarrhoea about a week before the patient began to feel ill, and was recovering.

Several severe paroxysms came on at night during the week before admission. Much headache and dry throat: no diarrhoea, no abnormal heat.

On admission. Ap. 27. Aneurysm. A well nourished woman - not flushed: skin fairly cool and dry (3 p.m.). Expression cheerful and intelligence good. Subacute headache: much weakness. P. 110 fairly good. Temp. 20. Tongue thickly coated. Heart: sounds rather distant, strength normal, lungs a few bronchitic sounds. Abdomen - normal - urine acid. Sp. 100. Slightly leukæmic, a trace of album.

Paroxysms. She was treated on admission with 10gr. Salicin gr. iii. hr. Hot Rhei 20 gr. com. Three loose light motions were passed next morning. She had a violent rigor on night of 28th - 29th, again on aft. of 29th, a lesser rigor on night of 29th - 30th on all occasions with much sweating & flushing - but entirely without pain or headache. No abnormality in the heart sounds - slight albuminuria was continued. No rigor after 30th, but nearly continuous profuse diaphoresis with much flushing. She was treated with Quin Sulf. 5 every 6 hours from the 29th April onwards - and was in no further discomfort than what seemed to arise from the sweating and hyperæcæmia. On the evening of May 4 she first made complaint of pain in her left side which rapidly grew acute. She compared it to the running of a spear into her side; was delirious during the greater part of the night May 4-5. When she came to herself about 9.30 a.m. on morning of 5th she complained of no further pain, the heart sounds were faintly audible but not otherwise abnormal; she died quietly two hours later.

A.T. Myers.