

No.	NAME	Age	Admitted	Died	Under the care of	Examination, at what time after death
110	Florence Elwood	10 ^{mo}	8 March 11	March 11	P. Cavafy	19 hrs

MORBID APPEARANCES.

External Appearances Body is well nourished, R. M. absent.

Ht 26 1/2 in
Wt 15 lbs

The Lungs and Trachea

The Trachea is somewhat but slightly injected. The Bronchi (the larger ones) are in a similar state. But the smaller ones are more expanded & contain some viscid slightly yellowish secretion.

The lungs in places have patches of consolidation which are wedge shaped & on section have a glassy appearance. They lay out these places sink in water.

There is considerable Emphysema a surface and at margins of lungs. There is also some interstitial Emphysema. Other organs appear natural.

J. Howard Brady

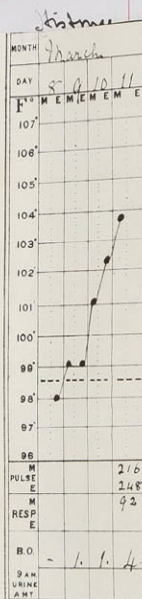
No. in Reg.
189

NATURE OF DISEASE.

415

Broncho-pneumonia

CASE.



The patient was a child aged 10 months. His mother brought him to the Hospital in the middle of the 8th and apparently took no further interest in the case.

The child was well nourished.

He died a week or two after food.

Breathing was hurried. There was some slight want of resonance on the base of the left lung - and a few crackles were heard there. On the right lung breathing sounds were harsh.

There was no cough or sputum.

Nothing abnormal was found in the abdomen.

Broncho pneumonia was diagnosed -

The child was treated with 3i - 4 to 5 - + Brandy 3i - daily.

Course.

Dyspnea increased over child died on the 11th March.

Richard S. S. S.

No.	NAME	Age	Admitted	Died	Under the care of	Examination, at what time after death
110	Florence Elwood	18 ^{mo}	8 th March	11 th March	D. Cavay	19 hrs

MORBID APPEARANCES.

External Appearances Body is well nourished, R. M. absent
Ht 26.5 in
Wt 15 lbs

The lungs and Trachea
The Trachea is somewhat but slightly injected
The Bronchi (the large ones) are in a similar state
But the smaller ones are more congested & contain
viscid slightly yellowish secretion:
The lungs in places have patches of consolidation
which are wedge shaped & in section have a
appearance: They vary in size & are situated in
There is considerable Emphysema a surface area
at margins of lungs: There is also some interstitial
Emphysema: Other organs appear natural.

Richard Brandy

No. in Reg.
189

NATURE OF DISEASE.

415

Broncho-pneumonia

CASE.

History

The patient was a child aged 10 months. His
mother brought him to the Hospital on the night of the
8th and apparently took no further interest in the case.

The child was well nourished.

She had a cough 2 months after food.

Breathing was hurried. There was some slight want of
resonance on the base of the left lung - and a few
crepitations were heard there. Over the right lung
breathing sounds were harsh.

There was no evidence of fever.

Nothing abnormal was found in the abdomen.

Diagnosis
Prognosis

Broncho-pneumonia was diagnosed -
The child was treated with 3i - 4th day - +
Brandy 3i - daily.

Course.

Dyspnoea increased & the child died on the 11th March.

Richard S. S. S.