

No.	NAME	Age	Admitted	Died	Under the care of	Examination, at what time after death	No. in Reg' 1882	NATURE OF DISEASE.
194	Benjamin Flood	44	21 June	June 23	Mr Rouse	22 hours	1111	Fracture of base of Skull, Laceration of Left Frontal lobe of Brain -

MORBID APPEARANCES

CASE

Gen appear - Height 5ft 6 in - Hair, Brown getting gray
Body, well nourished & very muscular

Pleura
Emphysema
Hypostatic
Congestion
Each Lung emphysematous -
Very hypostatically congested in posterior
portion, the lower portion in each
being quite black -

Heart - 12 oz. Uncontracted - Healthy -

Aorta
Atheroma
Slight, atheromatous -

Liver 3 lbs 15 - Healthy -

Spleen 4 oz - Normal

Kidneys
Adherent Capsule
10 oz Capsule adherent
Cortical portion infested -

Brain
Lacerated
Blood &
Travasated
The whole of the left side of brain was covered
with semi-coagulated blood, the quantity in
base being very great - The anterior left lobe of
brain was greatly lacerated on under surface
as represented in above diagram where
colored red the surface covered with blood clot.

Skull
Blood extravasated
between dura mater
& bone
In the right-cerebellar fossa the Dura Mater
was raised from bone by extravasated blood
The part implicated is represented in the above
diagram encircled by a blue line -

Continued on 133.

This man was stated to have fallen some 16 feet
down from a tall chimney on to his head - He was
and brought to St. George's
intemperate habits.

pale - Cold - collapsed
pupils equal - Pulse
his axis - No subconjunctival
discharge from the eyes - no
paralysis. The next day he
vomiting - putting out his
He lay in bed curled up on
examination - The second day
he became quite unconscious
pupils insensible to light - Slight
right facial palsy - Pulse 140
no convulsions - no sickness
ceased and he died after being
out 12 hours.

G. R. Turner -

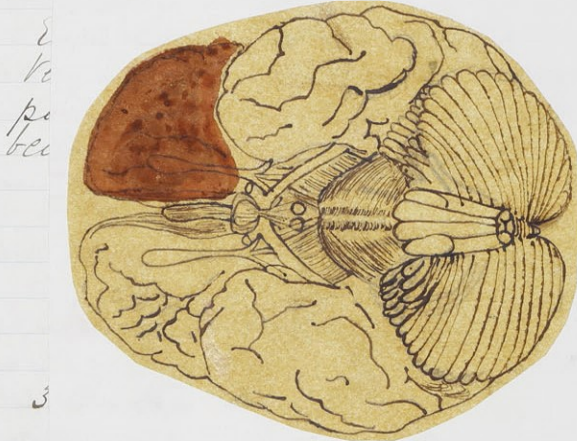
No.	NAME	Age	Admitted	Died	Under the care of	Examination, at what time after death
194	Benjamin Hood	44	21 June	June 23	Mr Rouse	22 hours

MORBID APPEARANCES

Gen. appear

Height 5 ft 6 in. Hair, Brown getting gray
Body well nourished & very muscular

Pleura
Emphysema
Hypostatic
Congestion



Benj Hood 194
1882

Heart

Aorta
Atheroma
Liver

3

Spleen

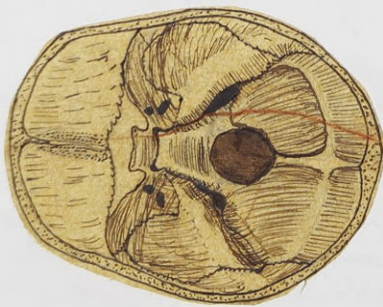
4 oz - Normal

Kidneys
Adherent Capsule

10 oz
Cortical poor

Brain
Lacerated
Blood extravasated

The whole of the brain
with semicoagulated
base being very granular
Brain was greatly
as represented in
colored under the sur



Benj Hood 194
1882

Skull
Blood extravasated
between internal
& bone

In the right-cerebrum
was raised from bone by extravasated blood
The part implicated is represented in the above
diagram encircled by a blue line -

Continued on 133.

No. in Reg
1882

NATURE OF DISEASE

Fracture of base of Skull, Laceration of Left-frontal
lobe of Brain -

CASE

This man was stated to have fallen some 16 feet
from some scaffolding on to his head. He was
picked up insensible and brought to St. George's.
It was said he was of intemperate habits.
On admission - He was pale - cold - collapsed
in a state of concussion - pupils equal - Pulse
feeble - Some slight epistaxis - no subconjunctival
Ecchymosis - no hæmorrhage from the ears - no
hæmatemesis - no paralysis. The next day he
could be roused by shouting - putting out his
tongue when told to - He lay in bed curled up on
one side - resisting examination - The second day
after the accident he became quite unconscious
with dilated pupils insensible to light - slight
stertor - slight right facial palsy - Pulse 140
cyanosis of face. no convulsions - no sickness
The stupor increased and he died after being
unconscious about 12 hours.

G. R. Turner -