

No.	NAME	Age	Admitted	Died	Under the care of	Examination, at what time after death
2	James Hogginton	6	30 Dec	Jan 2	D <sup>r</sup> Madham	16 hrs

MORBID APPEARANCES.

Gen. Appear. Height 3f 3. Abdomen prominent. Surface of body pigmented.

Pleuroc. Old adhesions on left side  
Adhesions at right base.

Lungs. 14 oz. At base of right lobe a thin cloudy mass the size of a split pea. Apices pale, and free from signs of tuberc.

Liver. 1lb. 1 oz. Healthy.

Spleen 1 oz. Healthy.

Kidneys 5 oz. Healthy.

Brain 2lb. 13 oz. Enlarged, congested, soft, inflamed. A quantity of greenish lymph covers the surface of the right hemisphere, and the parts at the base of the brain are concealed from view, by a thick purulent mass of lymph. The Sylvian fissures are matted together by inflammation, and the greenish lymph extends down the spinal canal, through the great foramen. The ventricles are greatly dilated, the septum lucidum soft and suppurated, and the Corpora Striata, and thalam, soft and semi-diffused.

On Examining the vessels, small granular tubercles can be found with the naked eye, upon the branches of the left Middle Cerebral artery, and more abundantly upon the choroidal plexuses of veins.

Am Sheld.

1884  
No. in Reg.  
1884/5

NATURE OF DISEASE.

1889 Tubercular Meningitis

CASE.

History

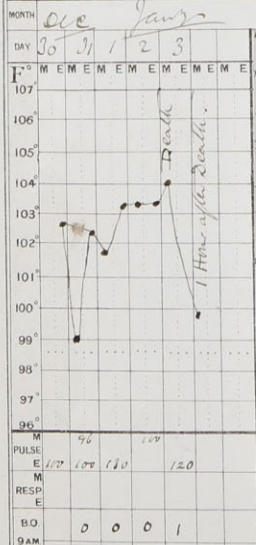
Admission.

A small boy, with no history of illness, or of weakness - nor any history of convulsions among members of the same family. One uncle & one aunt had died of phthisis on the mother's side. In the lowest standard in the Board School - had had no infantile diseases; & was playing with other children on the 25<sup>th</sup> December, when he complained of headache, which to him developed a cough on the 28<sup>th</sup> & vomited on the 30<sup>th</sup>. Was sent to Hospital that afternoon. Fair child, with various brown discolourations of abdomen - feces puritan in bed, slight strabismus, conscious up to 10 o'clock for what he wants - temp on admission 103°; being irritable - & screaming at times, with fits of screaming - abdomen slightly retracted no trace cerebral - Lungs, pulmonary clear, with exception of Rapes, other breathing harsh & few moist rales - heart sounds clear, a normal. urine. 4 p 1025, no sugar, but a trace of albumen.

Progress.

Hoarseness continued day & night, the next day after admission he was unconscious, with a well-marked arterial & venous pulse, respiration 18, but once or twice of the

PATIENTS NAME James Hogginton  
PHYSICIAN OR SURGEON Dr. Madham



Plots of Rapes, pupils equal, not contracted, with contracted - next day being elevated to separation with occasional cerebral cry - a sharp heavy some loss of power over left arm & leg on the 3<sup>rd</sup> day after which rapidly increased till the evening when it became distinct - on the 2<sup>nd</sup> January, decubitis on left side - left eye inflamed, & strabismus - abdomen distended, breathing at bases tubular - a rough & occasional clicks. Respiration noisy, irregular with periods of apnea, succeeded by fresh periods of full respirations - his temp continued steadily about 103°; & his hoarseness ceased altogether, in a comatose state at 10 P.M.

H. T. Griffiths.

No.	NAME	Age	Admitted	Died	Under the care of	Examination, at what time after death
2	James Hogginbottom	6	30 Dec	Jan 2	D <sup>r</sup> Madham	16 hrs

MORBID APPEARANCES.

Gen. Appar. Height 3f 3. Abdomen prominent. Surface of body pigmented.

Pleuroc. Old adhesions on left side. Adhesions at right base.

Lungs. 14 oz. At base of right two or three cloudy masses the size of a split pea. Apices pale, and free from signs of tuberc.

Liver. 1 lb. 1 oz. Healthy.

Spleen 1 oz. Healthy.

Kidneys 5 B. Healthy.

Brain 2 lb. 10 oz. Enlarged, congested, soft. A quantity of greenish lymph covers the right hemisphere, and the parts at the base are concealed from view, by a thick mass of lymph. The Sylvian fissures are matted together by inflammation, and the greenish lymph extends down the spinal canal, through the great foramen. The ventricles are greatly dilated, the septum lucidum soft and perforated, and the Corpora Striata, and thalam, soft and semi-diffuent.

On examining the vessels, small granular tubercles can be found with the naked eye, upon the branches of the left Middle cerebral artery, and more abundantly upon the choroidal plexuses of veins.

Am Sheld.

1884  
No. in Reg.  
1884

NATURE OF DISEASE.

1889 Tubercular Meningitis

CASE.

History

Admission.

A small boy, with no history of illness, or of unusual - nor any history of convulsions among members of the same family. An uncle & an aunt had died of phthisis as the mother told. In the lowest standard in the Board School - had had no infantile disease; & was playing with other children as the 25<sup>th</sup> December, when he complained of headache, next to this, developed a cough on the 28<sup>th</sup>; & vomited on the 30<sup>th</sup>. Illness similar - & was brought to Hospital there afternoon. Fair child, with various brown discolourations of abdomen, flexed position in bed, slight strabismus, conscious as far as to care for what he wants - temp on admission 105° being invariable - & moaning at times, with fits of screaming - abdomen slightly retracted no trace cerebral - lungs, pulmonary clear, with exception of R apex, where breathing harsh & few moist sounds - heart sounds clear, a normal. urine. 4 p 1025, no sugar, but a trace of albumen.

Progress.

moaning continued day & night, the next day after admission he was unconscious, with a high temperature, irregular quick pulse, respiration 18, but once or twice of the Cheyne Stokes characteristic seen. Pains of Rectum, pupils equal, not contracted, constipation - urine drawn off not contracted - each day being elapsed to separation ward, his moaning continued, with occasional cerebral cry - & at night being more violent - some loss of power over left arm & leg as the 3<sup>rd</sup> day after admission, which rapidly increased till the evening when it became distinct paralysis - on the 2<sup>nd</sup> January, death on left side - left eye inflamed, & phthisis, with strabismus. abdomen distended, breathing at bases tubular - & at apices rough & occasional creaks. Respiration noisy, irregular with complete periods of apnea, succeeded by fresh periods of full respirations - his temperature continued steadily about 105°: & his moaning ceased altogether. He died in a comatose state at 10 P.M.

H. T. Griffiths.